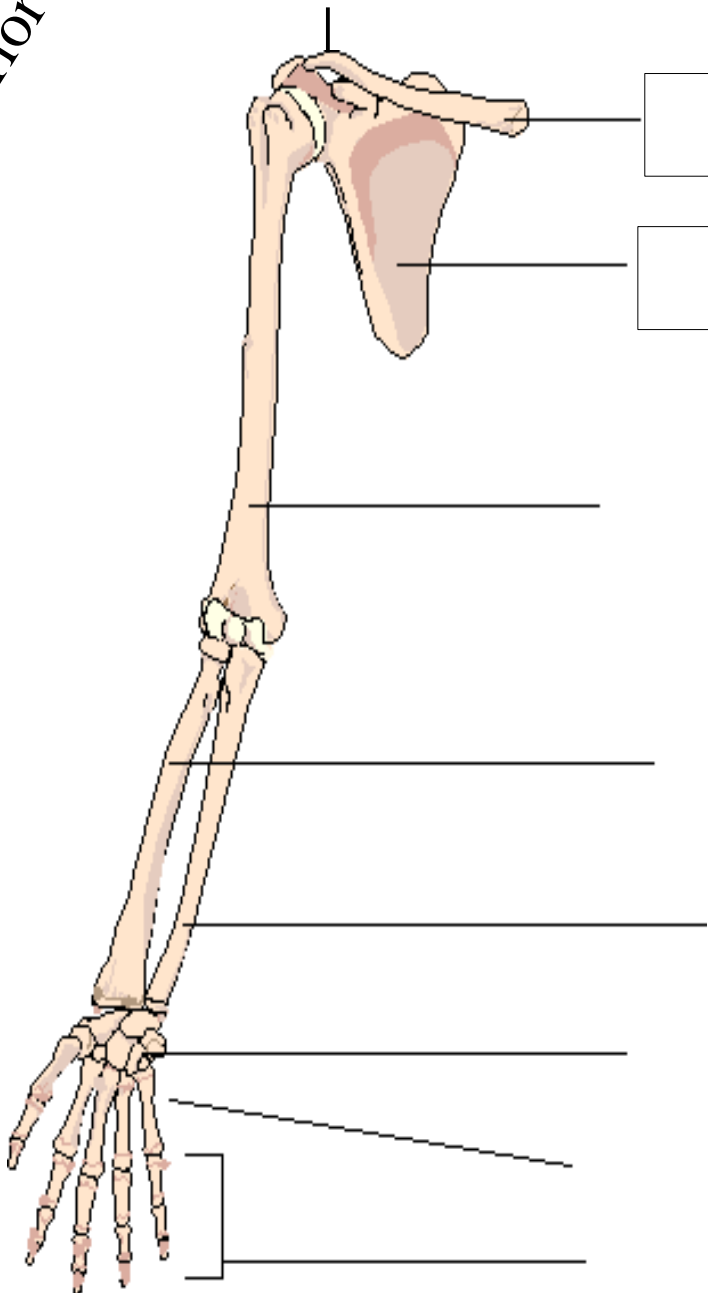


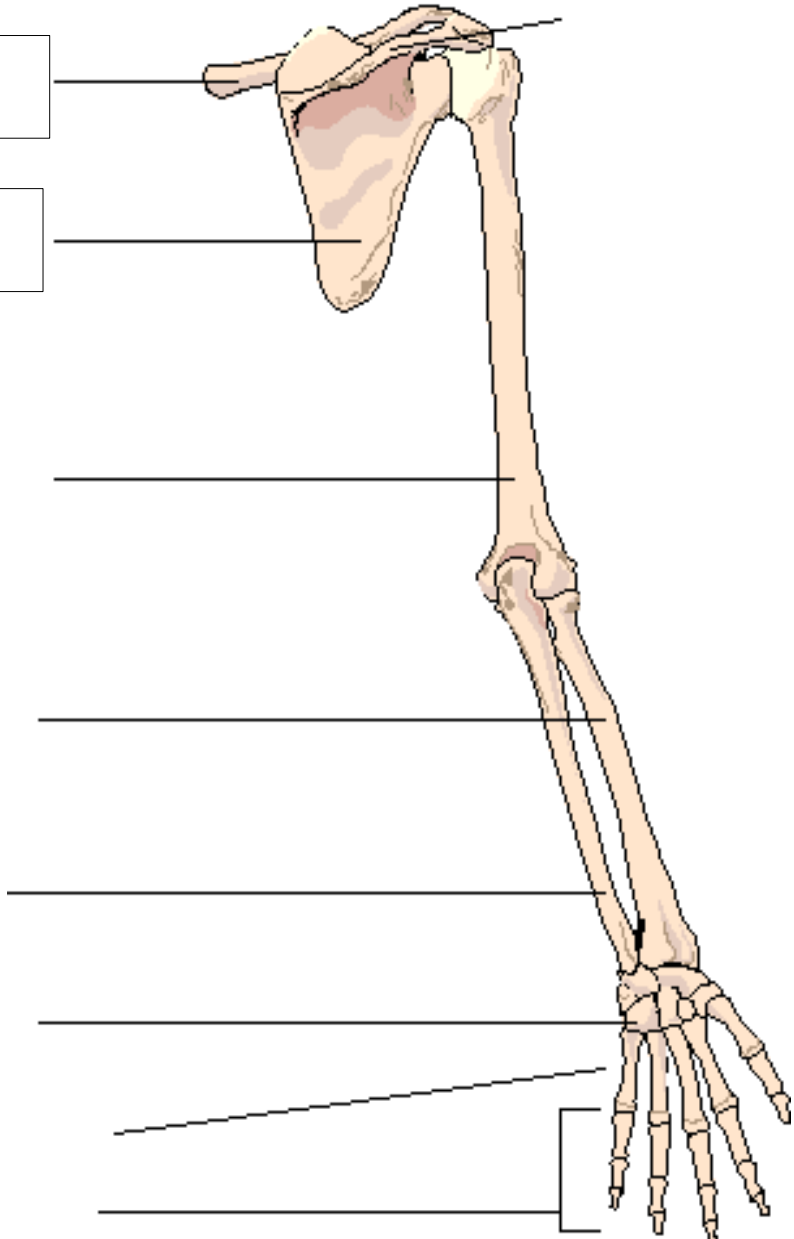
Upper Limb

Anterior View

Posterior View

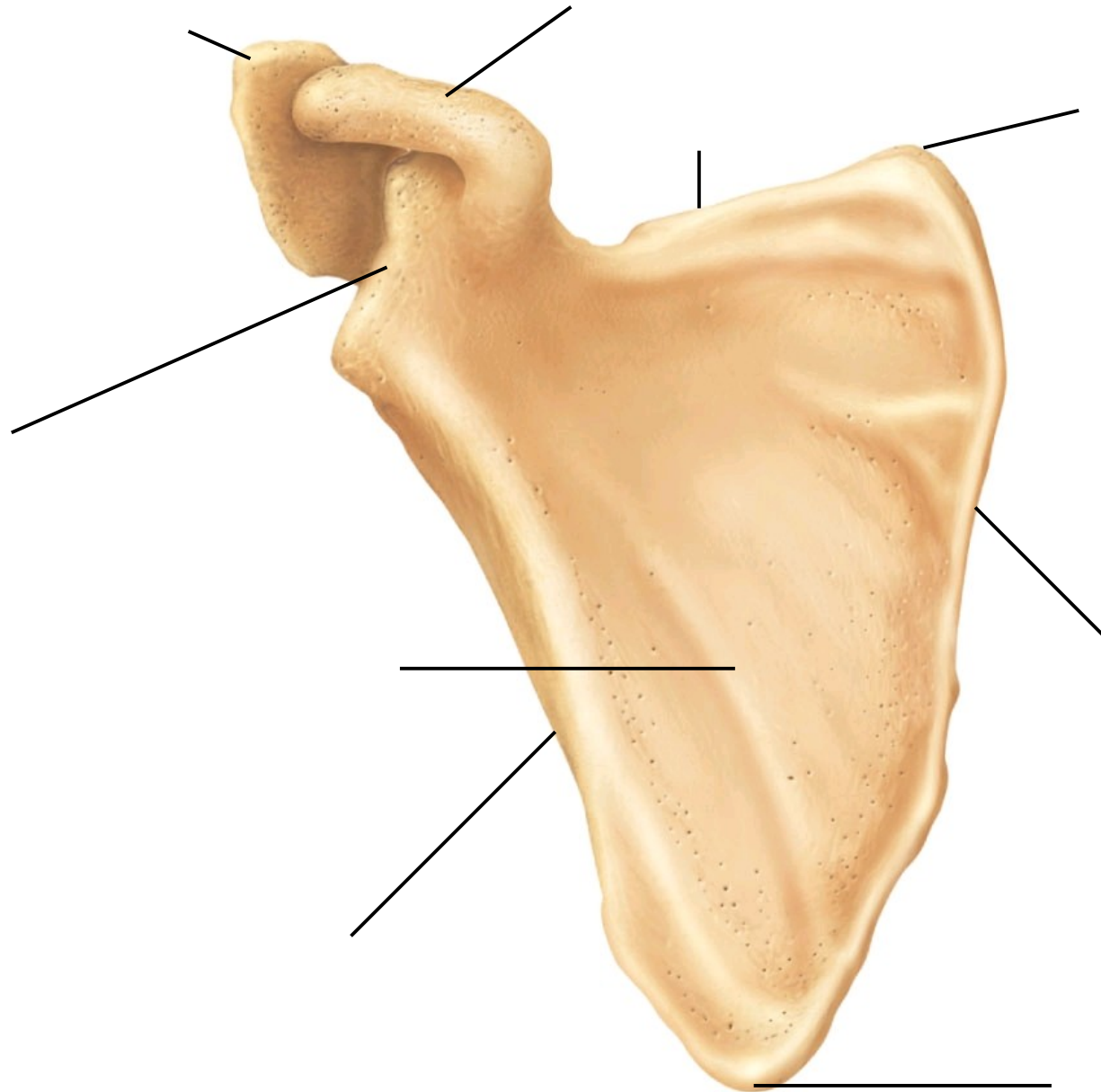
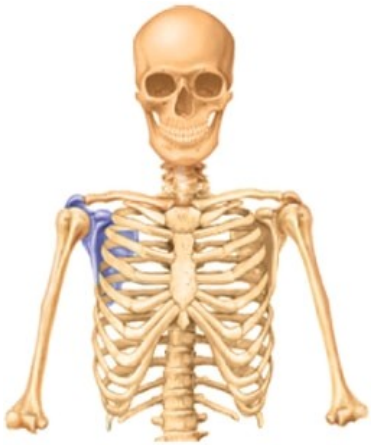

Two empty rectangular boxes for labeling the humerus in the anterior view.



One empty rectangular box for labeling the hand area in the posterior view.


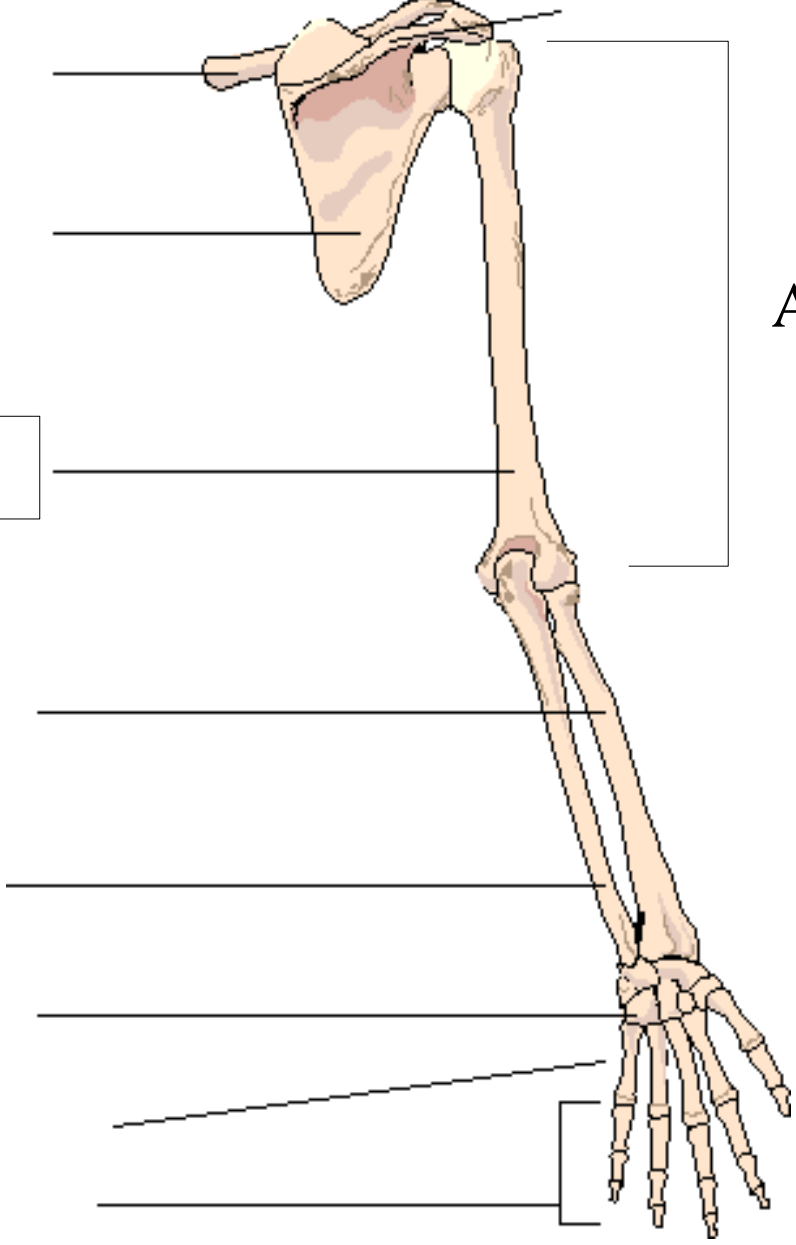
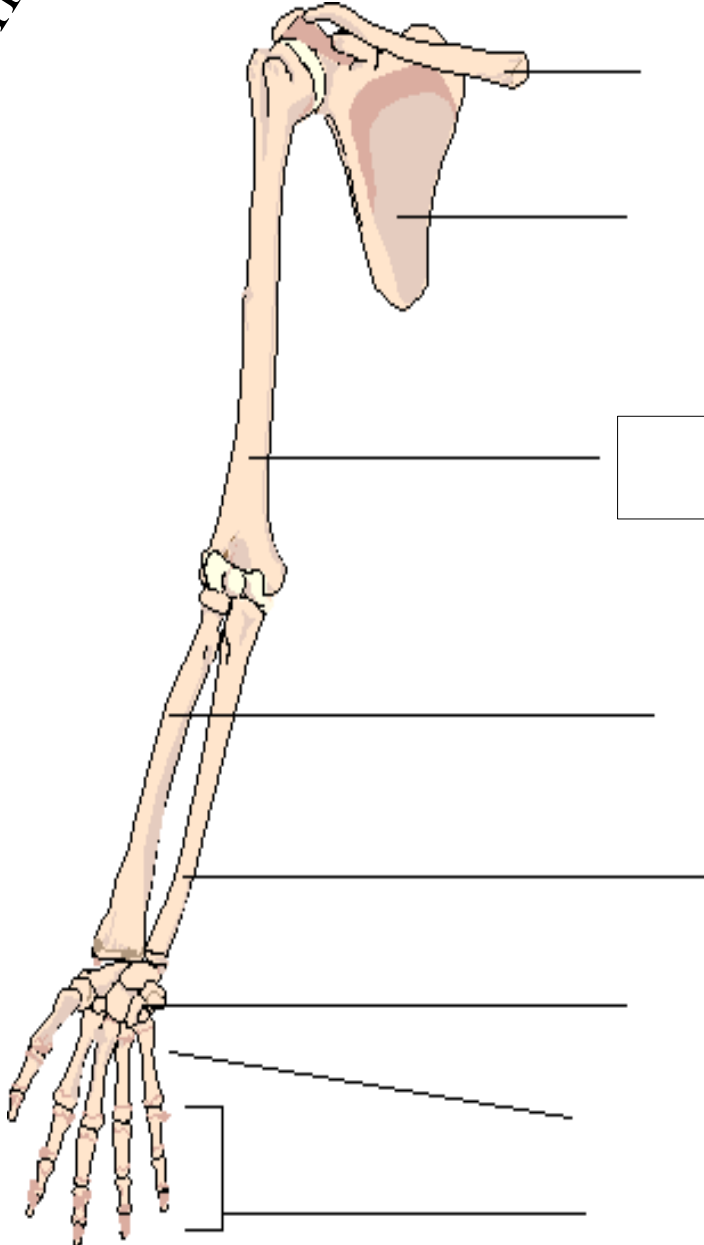
Scapula Markings



Upper Limb

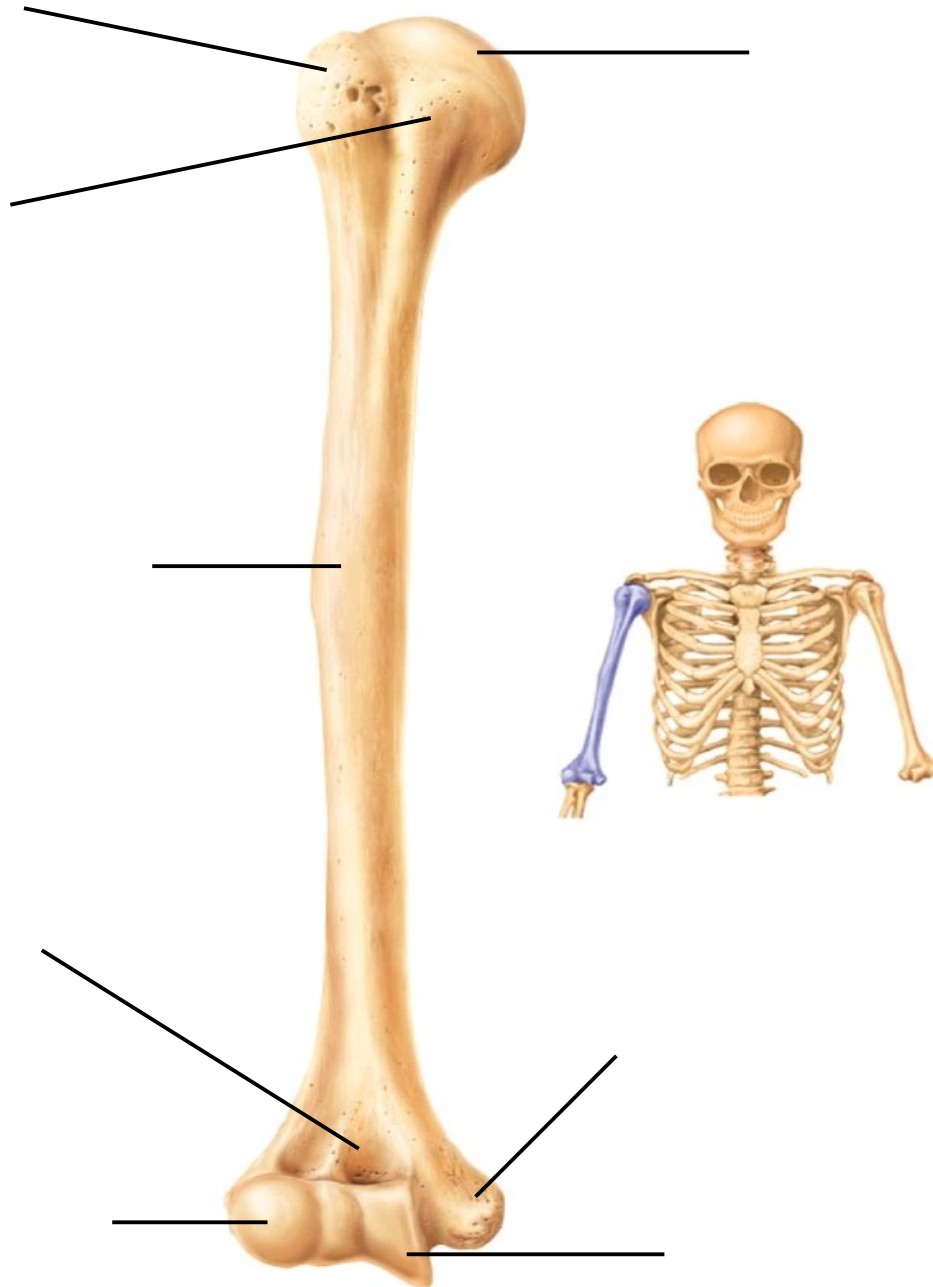
Anterior View

Posterior View

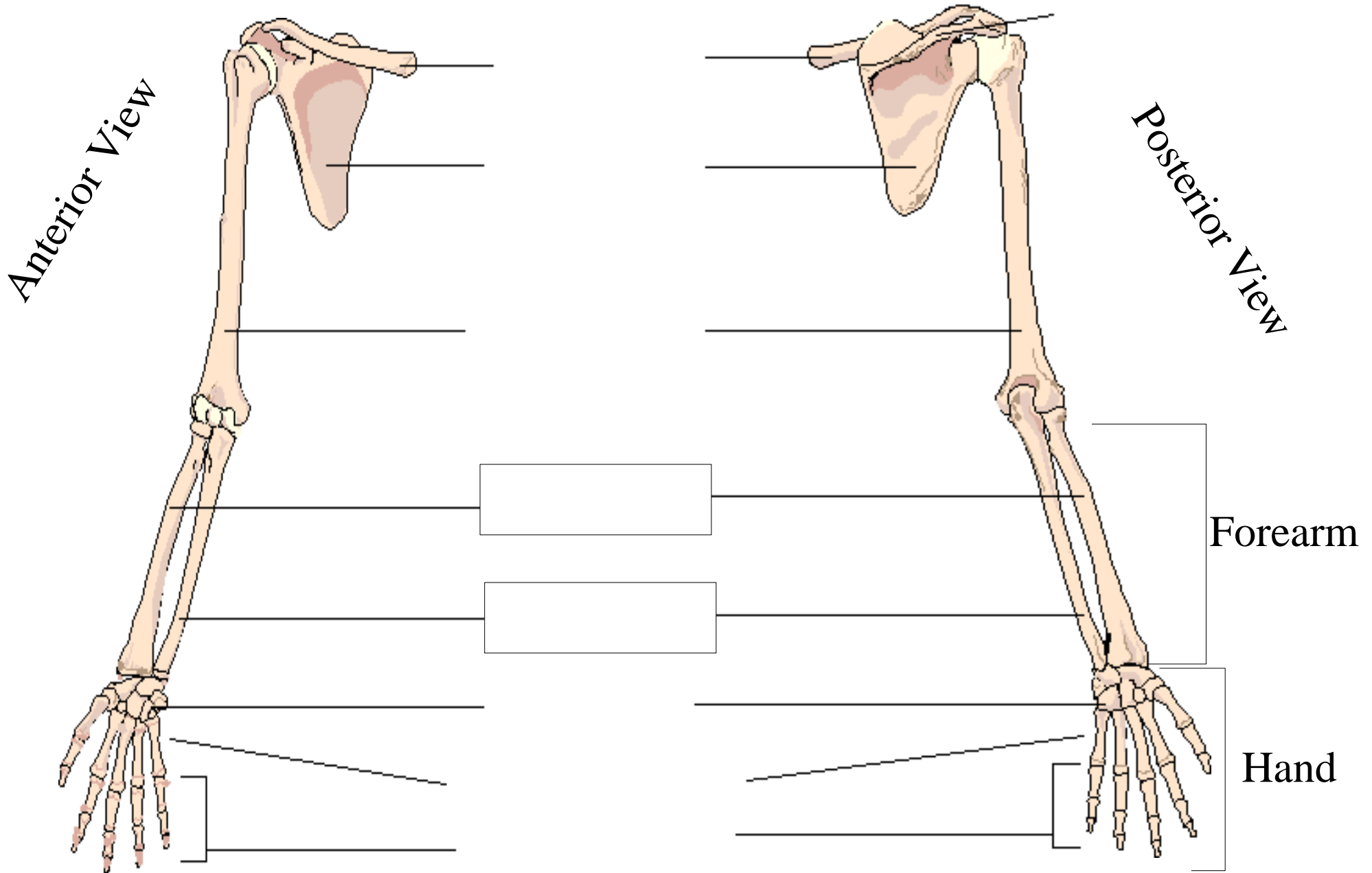


Arm

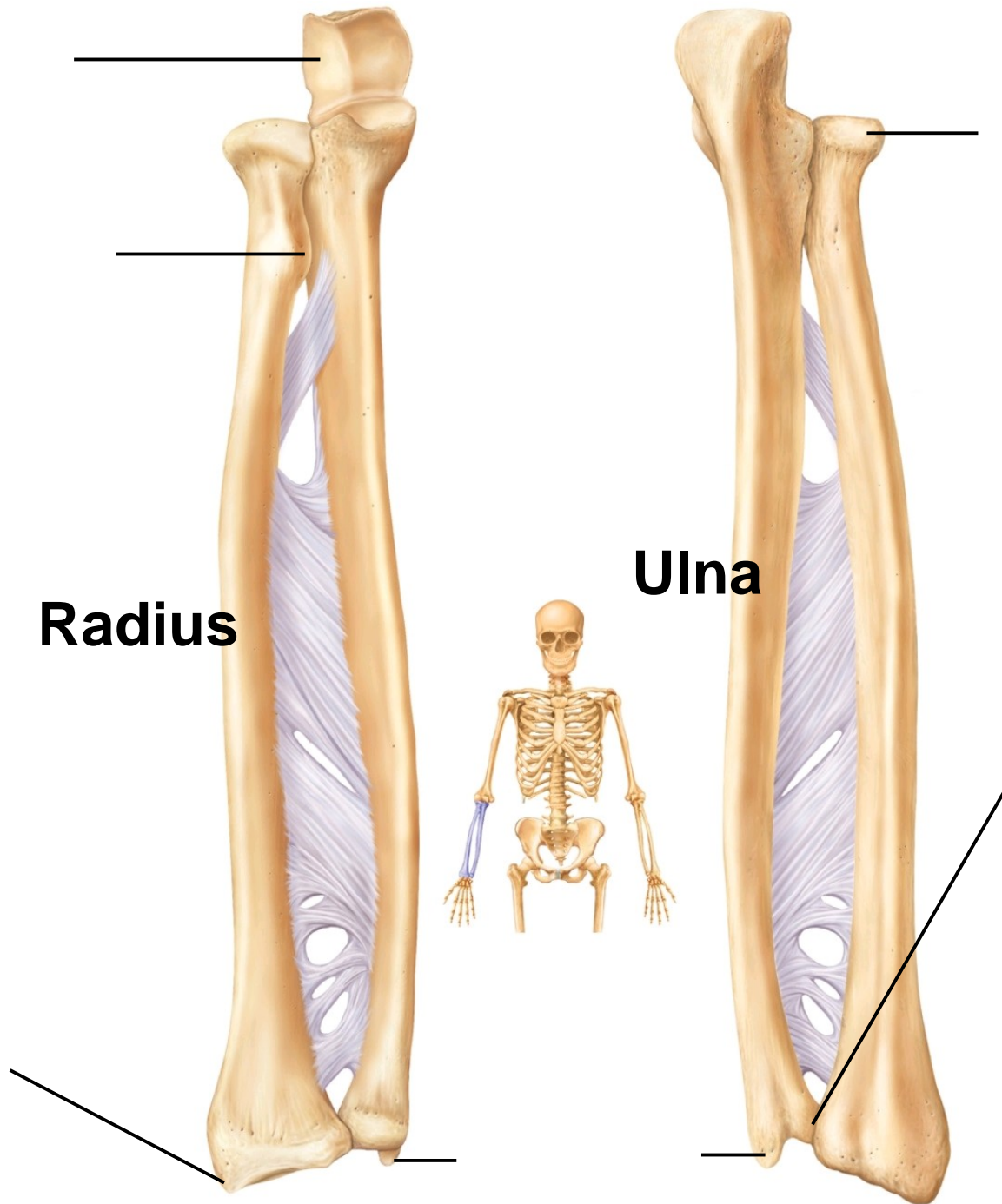
Humerus Markings



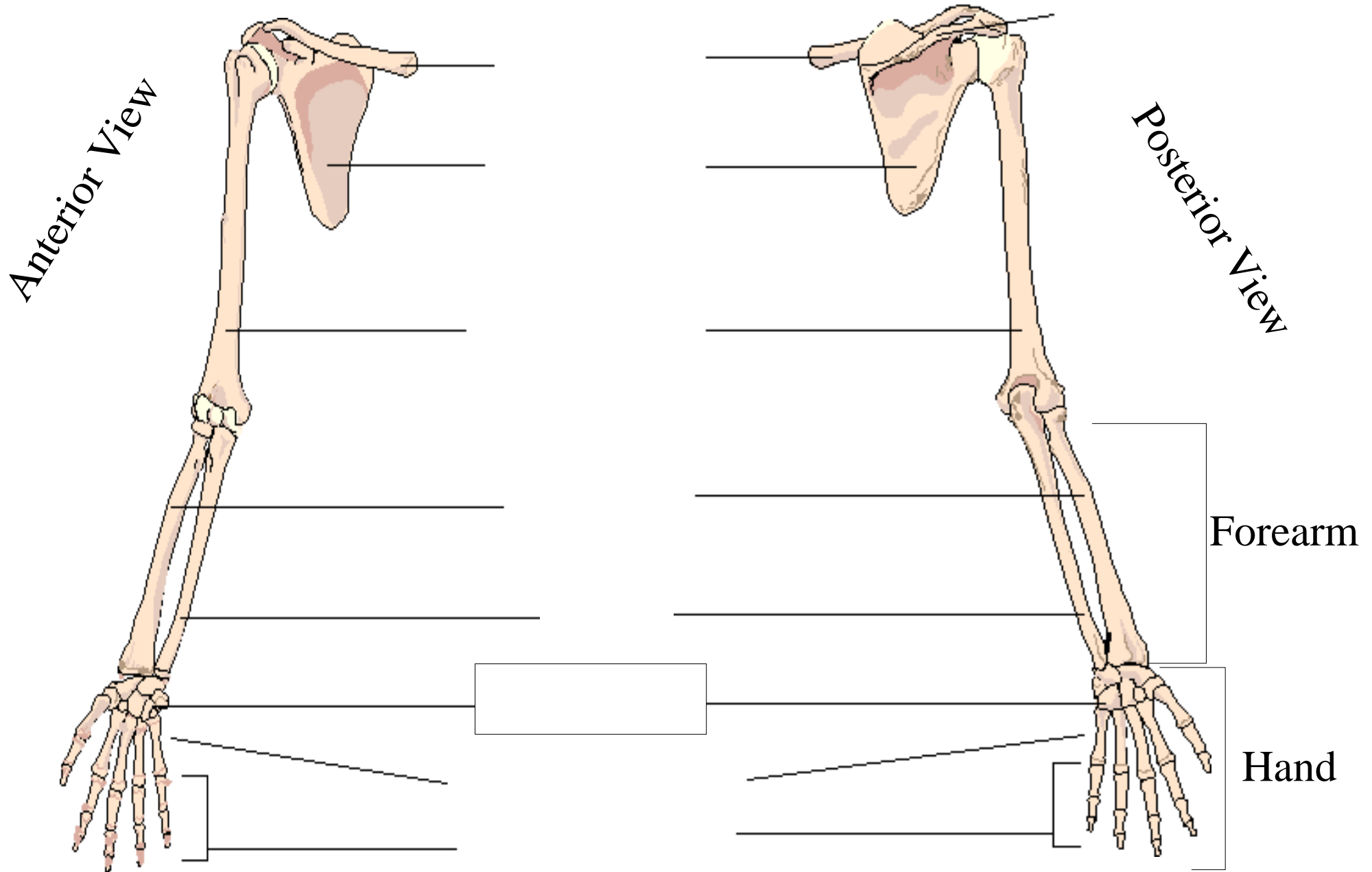
Upper Limb



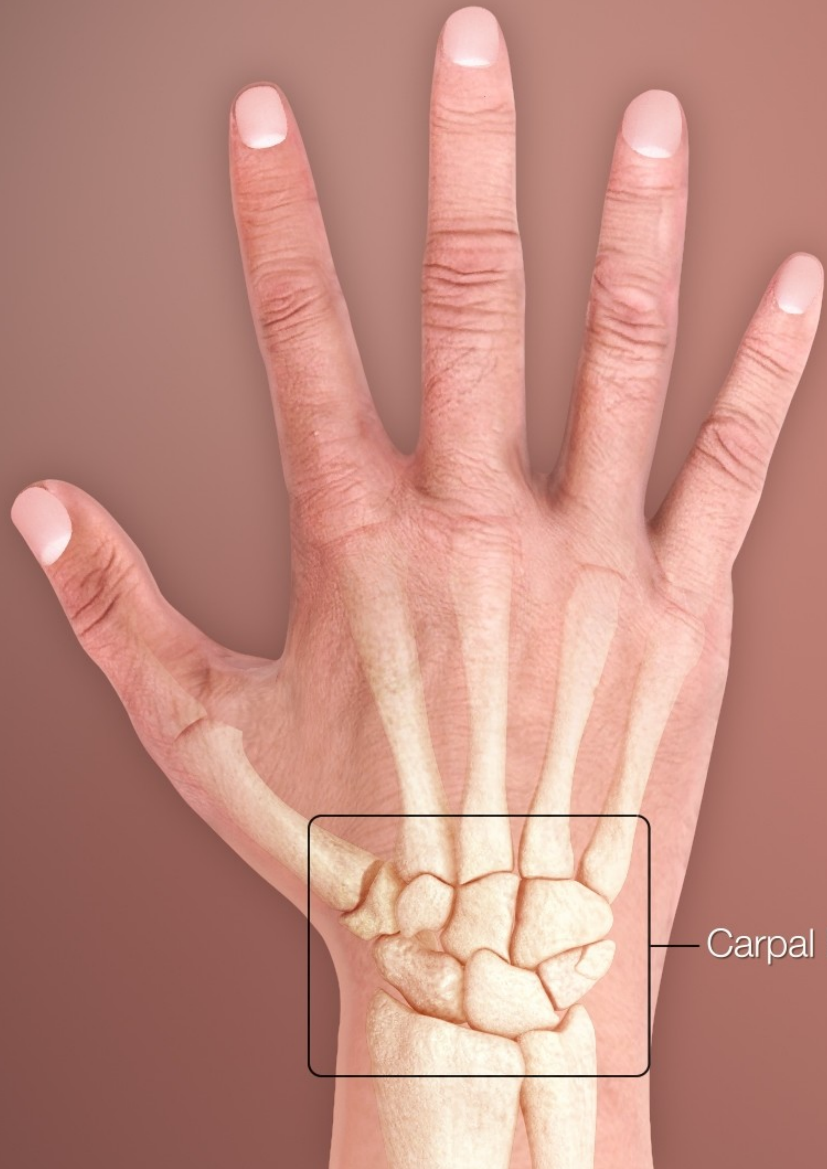
Forearm Markings



Upper Limb

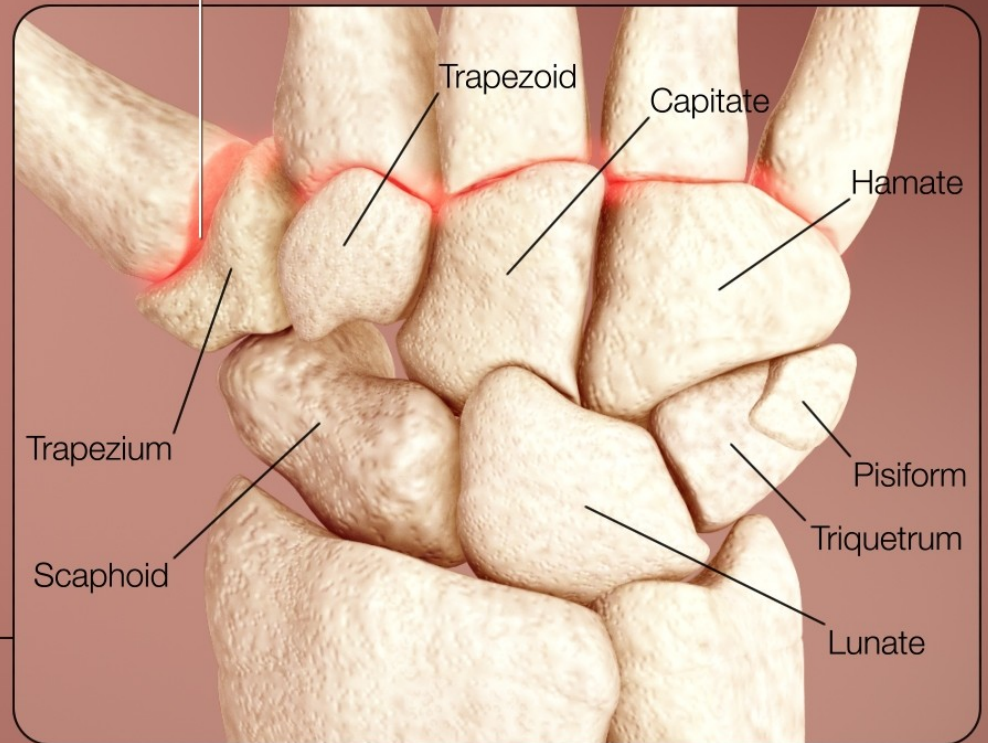


Carpals



Carpal bones

Carpometacarpal joint



Trapezoid

Capitate

Hamate

Pisiform

Triquetrum

Lunate

Trapezium

Scaphoid

Upper Limb

